Accepted Manuscript

Meta-Analysis Comparing the Frequency of Target-Vessel Revascularization of Drug-Coated Balloons or Second-Generation Drug-Eluting Stents for Coronary In-Stent Restenosis

Islam Y. Elgendy MD , Ahmed N. Mahmoud MD , Akram Y. Elgendy MD , Javier Cuesta MD , Fernando Rivero MD , Fernando Alfonso MD, PhD

PII: S0002-9149(19)30058-X
DOI: https://doi.org/10.1016/j.amjcard.2019.01.004
Reference: AJC 23722

To appear in: *The American Journal of Cardiology*

Received date: 21 December 2018

Please cite this article as: Islam Y. Elgendy MD , Ahmed N. Mahmoud MD , Akram Y. Elgendy MD , Javier Cuesta MD , Fernando Rivero MD , Fernando Alfonso MD, PhD , Meta-Analysis Comparing the Frequency of Target-Vessel Revascularization of Drug-Coated Balloons or Second-Generation Drug-Eluting Stents for Coronary In-Stent Restenosis, *The American Journal of Cardiology* (2019), doi: https://doi.org/10.1016/j.amjcard.2019.01.004

Meta-Analysis Comparing the Frequency of Target-Vessel Revascularization of Drug-Coated Balloons or Second-Generation Drug-Eluting Stents for Coronary In-Stent Restenosis

Islam Y. Elgendy, MD;[1] Ahmed N. Mahmoud, MD;[1] Akram Y. Elgendy, MD;[1] Javier Cuesta, MD;[2] Fernando Rivero, MD;[2] Fernando Alfonso, MD, PhD[2]

[1] Division of Cardiovascular Medicine, Department of Medicine, University of Florida, Gainesville, FL
[2] Department of Cardiology, Hospital Universitario de La Princesa, Universidad Autónoma de Madrid. IIS-IP. Madrid, Spain

Running title: DCB or DES for ISR

Disclosure: All the authors have no conflicts of interest to disclose

Corresponding author:
Islam Y. Elgendy, MD

Division of Cardiovascular Medicine, Department of Medicine

University of Florida

1600 SW Archer Road, P.O. Box 100288

Gainesville, FL, USA 32610

Tel: 352.273.9089

Fax: 352.392.3606

Email: iyelgendy@gmail.com

Coronary in-stent restenosis (ISR) remains challenging even in the era of second-generation drug-eluting stents (DES).[1] Drug-coated balloons (DCB) have emerged as an appealing modality for treatment of ISR. Randomized trials comparing DCB and second-generation DES for ISR have been underpowered to determine a difference on clinical outcomes. Therefore, we aimed to conduct an updated meta-analysis of randomized trials to compare the impact of both modalities with a focus on clinical outcomes for any ISR (i.e., bare metal stent [BMS] or DES), and for DES-ISR separately.

Details of the previous meta-analysis have been described.[2] Briefly, randomized trials comparing DCB versus second-generation DES for any ISR were included. Summary estimates were constructed with a random effects model, and standardized mean differences (SMDs) were used for continuous outcomes. The primary outcome for this analysis was target lesion revascularization (TLR); TLR was chosen as the primary outcome since revascularization of other lesions in the same vessel (i.e., target vessel revascularization [TVR]) could dilute the potential differences in the efficacy between the two strategies. A subgroup analysis was performed for DES-ISR only. The secondary outcomes included TVR, major adverse cardiac events (MACE), myocardial infarction (MI), stent thrombosis, all-cause mortality, and the angiographic outcomes (i.e., in-segment minimum luminal diameter [MLD], diameter stenosis [DS], and late lumen loss [LLL]). The outcomes were reported at the longest available follow-up. For the purpose of this analysis, an updated search for these data sources was performed from February 2018 to December 2018.

The updated search identified 2 new randomized trials.[3,4] A total of 7 randomized trials with 1,363 patients were included (726 in the DCB arm and 637 in the second-generation DES arm). A paclitaxel-eluting balloon was the DCB utilized while the everolimus-eluting stent was the comparator except for one trial[4] which used a second-generation sirolimus-eluting stent. The mean reference vessel diameter ranged from 2.5-3.0 mm. At a mean of 8.2 months, DCB was associated with a lower in-segment MLD (1.87 mm versus 2.00 mm; SMD -0.22, 95% confidence interval [CI] -0.35-[-0.11], P<0.01), a higher in-segment DS (31.0% versus 26.6%; SMD 0.23, 95% CI 0.13-0.34, P<0.01), but a lower LLL (0.16 mm versus 0.23 mm; SMD -0.16, 95% CI -0.27-[-0.05], P<0.01) (**Figure-A**). DCB was associated with an increased risk of TLR (11.4% versus 5.6%; risk ratio [RR] 1.83, 95% CI 1.07-3.13, P=0.03, I^2= 14%) at a mean of 27 months. This effect was noted on the analysis limited to DES-ISR only (RR 1.88, 95% CI 1.08-3.20, P=0.02, I^2= 4%). There was no difference between both strategies in terms of the secondary clinical outcomes (**Figure-B**).

In this meta-analysis of 7 randomized trials with 1,363 patients with any ISR (i.e., BMS or DES), we demonstrated that DCB was associated with a higher incidence of TLR at 27 months. This observation was noted even when limited to DES-ISR only. The increased incidence of TLR with DCB could be related to the lower in-segment MLD and higher diameter stenosis at a mean 8.2 months. Based on our estimates (i.e., RR of 1.83 and 5.6% event rate in the DES arm), 635 patients in each arm would be needed to achieve 80% power for TLR, therefore by including these 2 new trials, this meta-analysis is adequately powered to detect a difference between both strategies on TLR. These findings suggest that optimal late angiographic and clinical outcomes are achieved with

second-generation DES. It is reassuring that there were no differences between both strategies on the incidence of MACE, TVR, MI, stent thrombosis, and all-cause mortality. Thus, future studies should focus on identifying lesions that might obtain excellent angiographic and clinical outcomes with DCB. Although this analysis might be limited by the methodological heterogeneity due to the different types of paclitaxel-eluting balloons, we noted minimal statistical heterogeneity for TLR.

This meta-analysis of randomized trials demonstrated that second-generation DES is associated with improved late TLR and angiographic outcomes compared with DCB for any ISR. This effect is noted when limited to DES-ISR. Further studies are needed to elucidate on the role of DCB for the management of ISR.

References:

1) Alfonso F, Byrne RA, Rivero F, Kastrati A. Current treatment of in-stent restenosis. *J Am Coll Cardiol* 2014;63:2659-2673.

2) Elgendy IY, Mahmoud AN, Elgendy AY, Mojadidi MK, Elbadawi A, Eshtehardi P, Pérez-Vizcayno MJ, Wayangankar SA, Jneid H, David Anderson R, Alfonso F. Drug-eluting balloons versus everolimus-eluting stents for in-stent restenosis: A meta-analysis of randomized trials. *Cardiovasc Revasc Med* 2018. doi: 10.1016/j.carrev.2018.08.010.

3) Wong YTA, Kang DY, Lee JB, Rha SW, Hong YJ, Shin ES, Her SH, Nam CW, Chung WY, Kim MH, Lee CH, Lee PH, Ahn JM, Kang SJ, Lee SW, Kim YH, Lee CW, Park SW, Park DW, Park SJ. Comparison of drug-eluting stents and drug-coated balloon for the treatment of drug-eluting coronary stent restenosis: A randomized RESTORE trial. *Am Heart J* 2018;197:35-42.

4) Jensen CJ, Richardt G, Tölg R, Erglis A, Skurk C, Jung W, Neumann FJ, Stangl K, Brachmann J, Fischer D, Mehilli J, Rieber J, Wiemer M, Schofer J, Sack S, Naber CK. Angiographic and clinical performance of a paclitaxel coated balloon compared to a 2nd generation sirolimus eluting stent in patients with in-stent restenosis- the BIOLUX randomized controlled trial. *EuroIntervention* 2018;14:1096-1103.

FIGURE LEGENDS

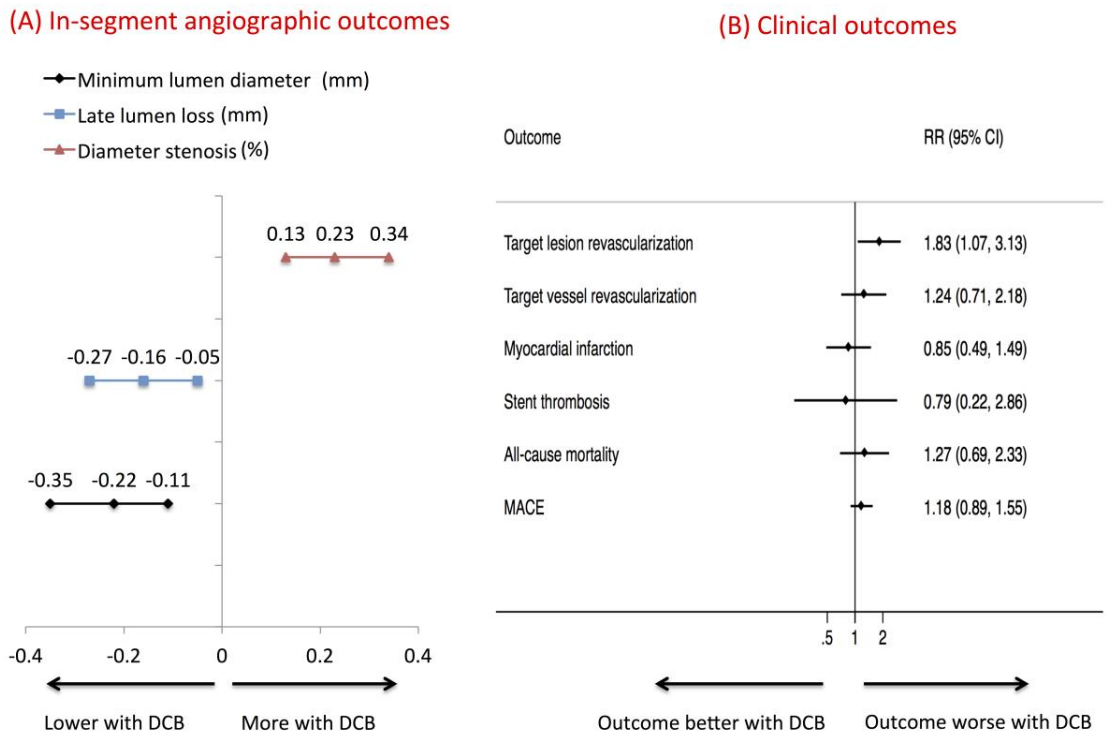

Figure: (A) Forest plot summary for in-segment angiographic outcomes (P values for all outcomes was <0.01); (B) Forest plot summary for clinical outcomes assessed in this meta-analysis (P value for significant for target lesion revascularization=0.03, but was non-significant for the remainder of the outcomes)